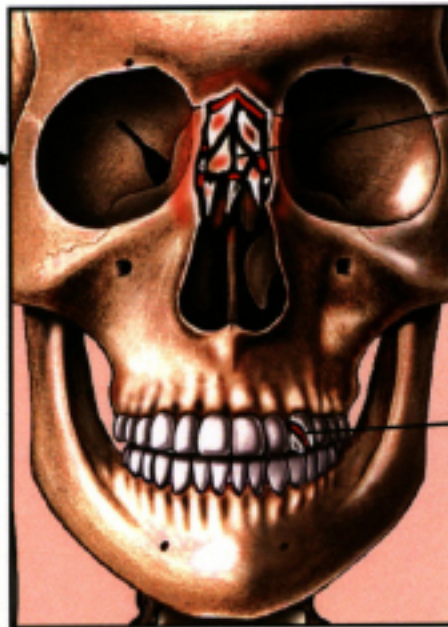
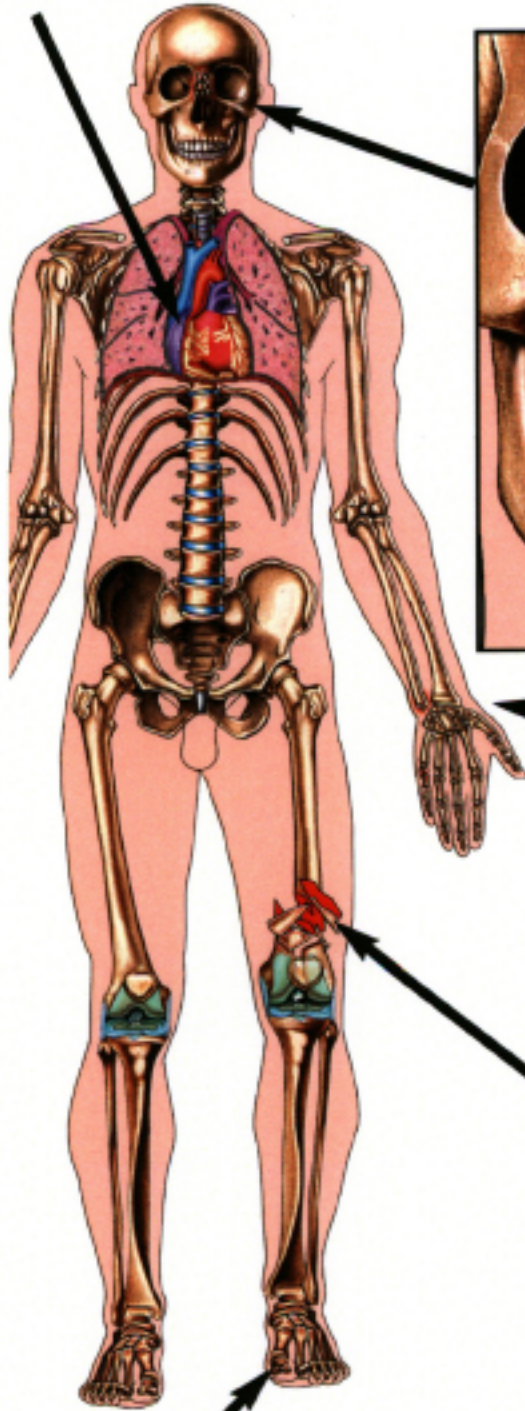


POST-IMPACT CONDITION

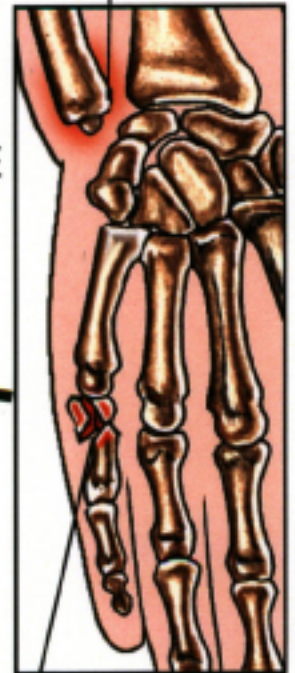
ATRIAL FIBRILLATION



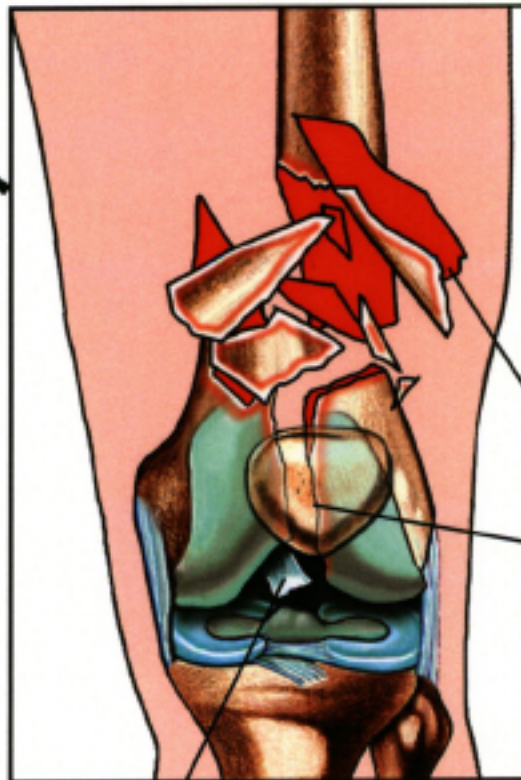
COMMINUTED
DEPRESSED
NASAL FRACTURE

LEFT
INCISOR
TOOTH
FRACTURE

LEFT WRIST
ULNAR
DISLOCATION

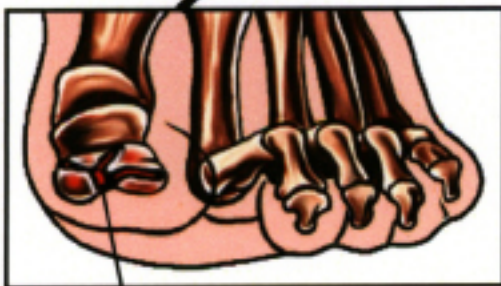

LEFT FINGER
PHALANGEAL
FRACTURE



LEFT KNEE
COMMINUTED
FEMORAL
FRACTURE

LEFT KNEE PCL RUPTURE



LEFT GREAT TOE
FRACTURE