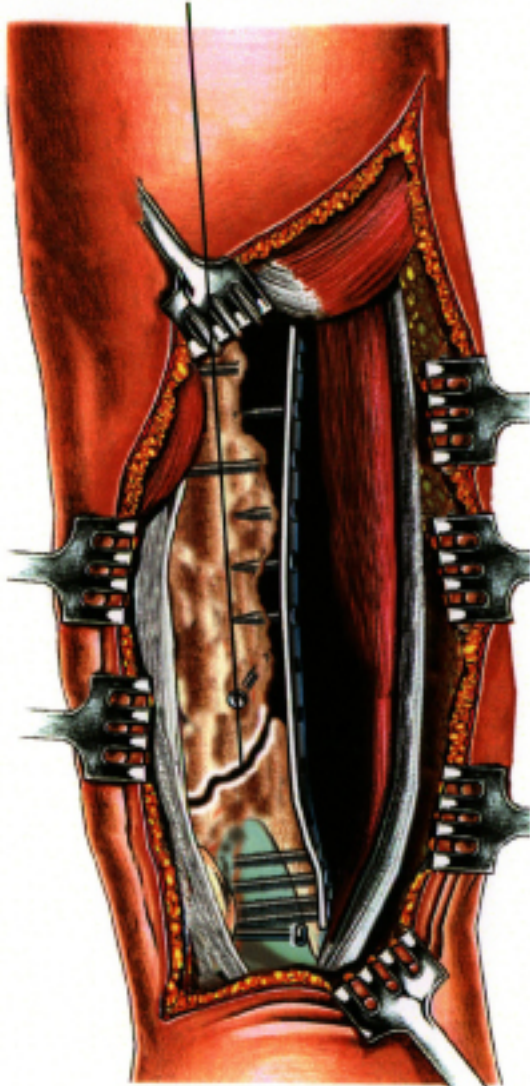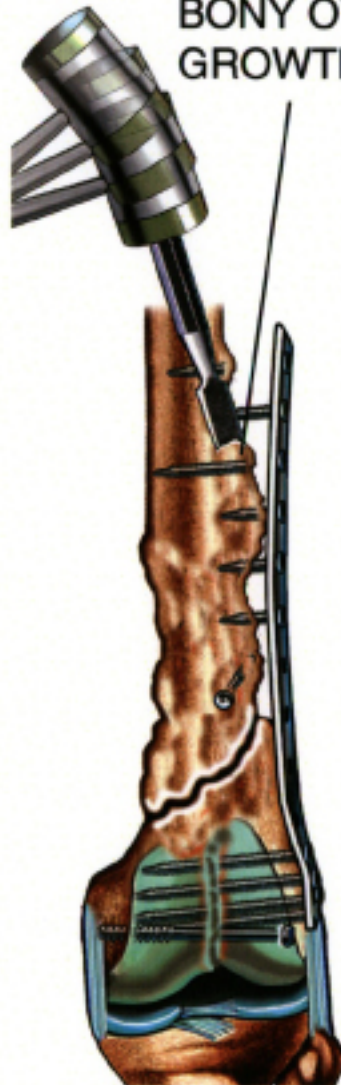


# LEFT KNEE SURGERY. 8/1/08

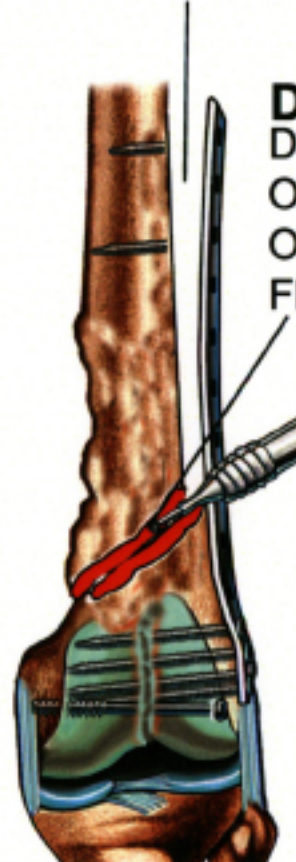
**A.**  
INCISION TO EXPOSE  
PLATE & NONUNION OF  
FEMORAL FRACTURE



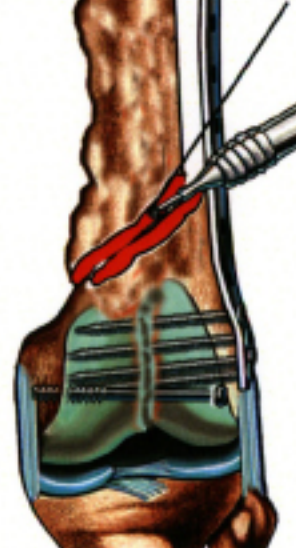
**B.** REMOVAL OF  
HYPERTROPHIC  
BONY OVER-  
GROWTH



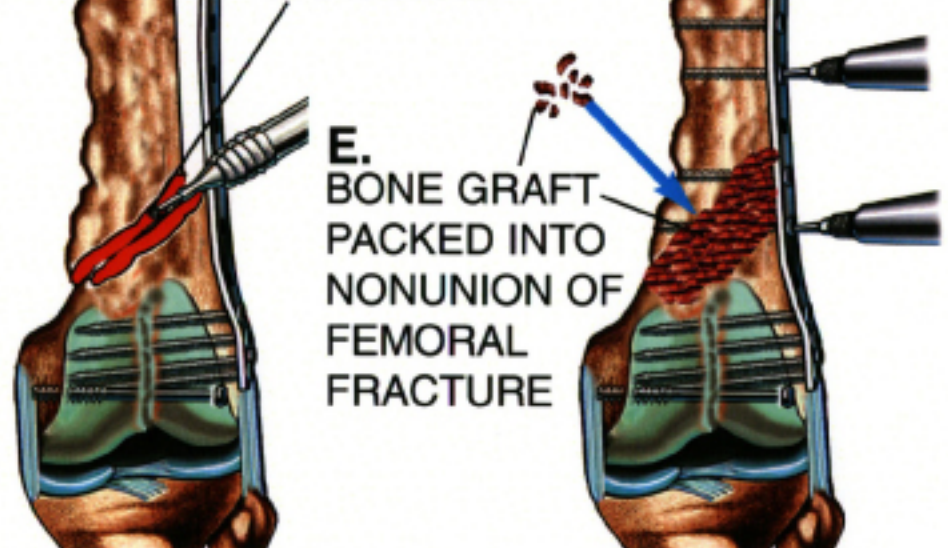
**C.**  
REMOVAL OF  
SCREWS FROM  
UPPER PLATE



**D.**  
DRILLING OUT  
OF NONUNION  
OF FEMORAL  
FRACTURE



**E.**  
BONE GRAFT  
PACKED INTO  
NONUNION OF  
FEMORAL  
FRACTURE



**F.**  
PLACEMENT  
OF NEW  
SCREWS TO  
FIXATE PLATE  
TO FEMUR

